

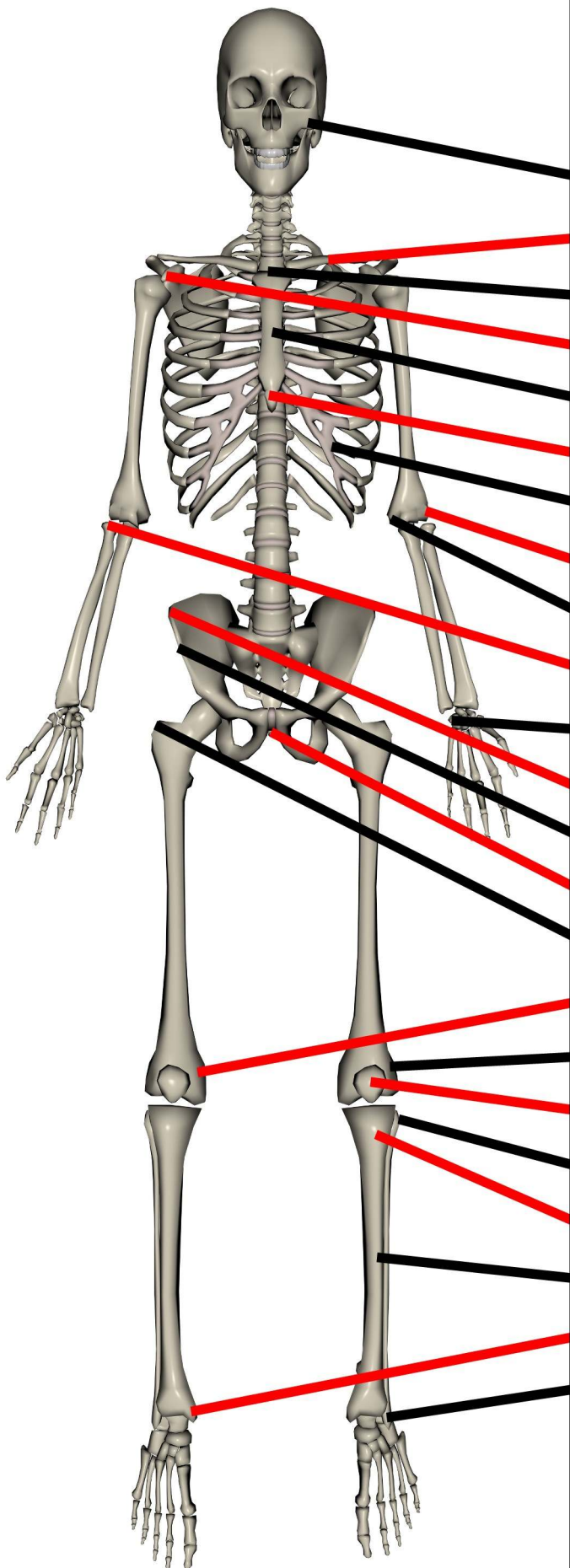
MASSAGENERD.COM

Presents

**Bone
Landmarks**

Bony Landmarks

(Anterior)



Zygomatic Bone

Clavicle

Sternal Notch

Coracoid Process of Scapula

Sternum

Xiphoid Process

Ribs

Lateral Epicondyle of Humerus

Medial Epicondyle of Humerus

Head of Radius

Pisiform

Iliac Crest

Anterior Superior Iliac Spine

Pubis Symphysis

Greater Trochanter of Femur

Medial Epicondyle of Femur

Lateral Epicondyle of Femur

Patella

Head of Fibula

Tuberosity of Tibia

Anterior Shaft of Tibia

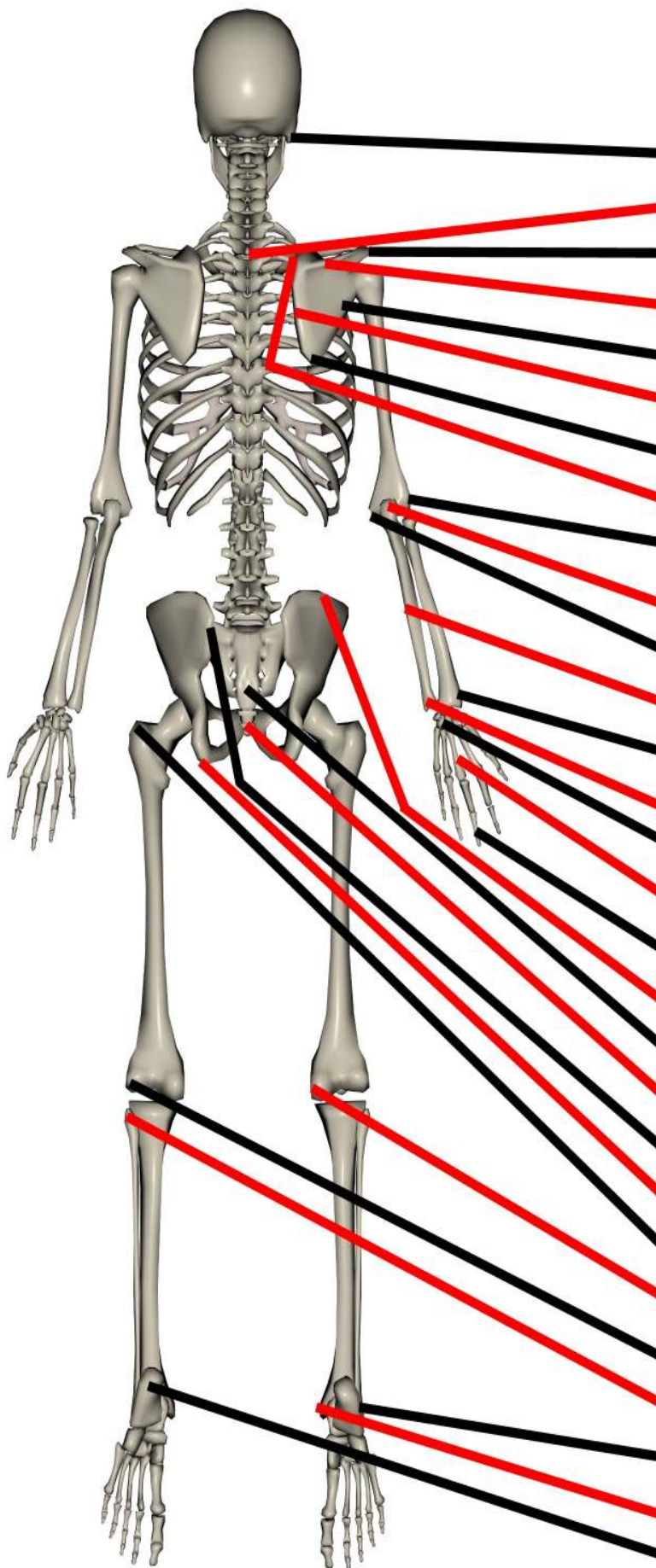
Medial Malleolus

Lateral Malleolus

www.MassageNerd.com

Bony Landmarks

(Posterior)



Mastoid Process of Temporal Bone

C7 Spinous Process

Acromion Process of Scapula

Spine of Scapula

Axillary Border of Scapula

Vertebral Border of Scapula

Inferior Angle of Scapula

Superior Angle of Scapula

Lateral Epicondyle of Humerus

Olecranon Proces of Ulna

Medial Epicondyle of Humerus

Posterior Border of Ulna

Styloid Process of Radius

Styloid Process of Ulna

Carpals

Metacarpals

Phalanges

Iliac Crest

Sacrum

Coccyx

Posterior Superior Iliac Spine (PSIS)

Ischial Tuberosity

Greater Trochanter of Femur

Medial Epicondyle of Femur

Lateral Epicondyle of Femur

Head of the Fibula

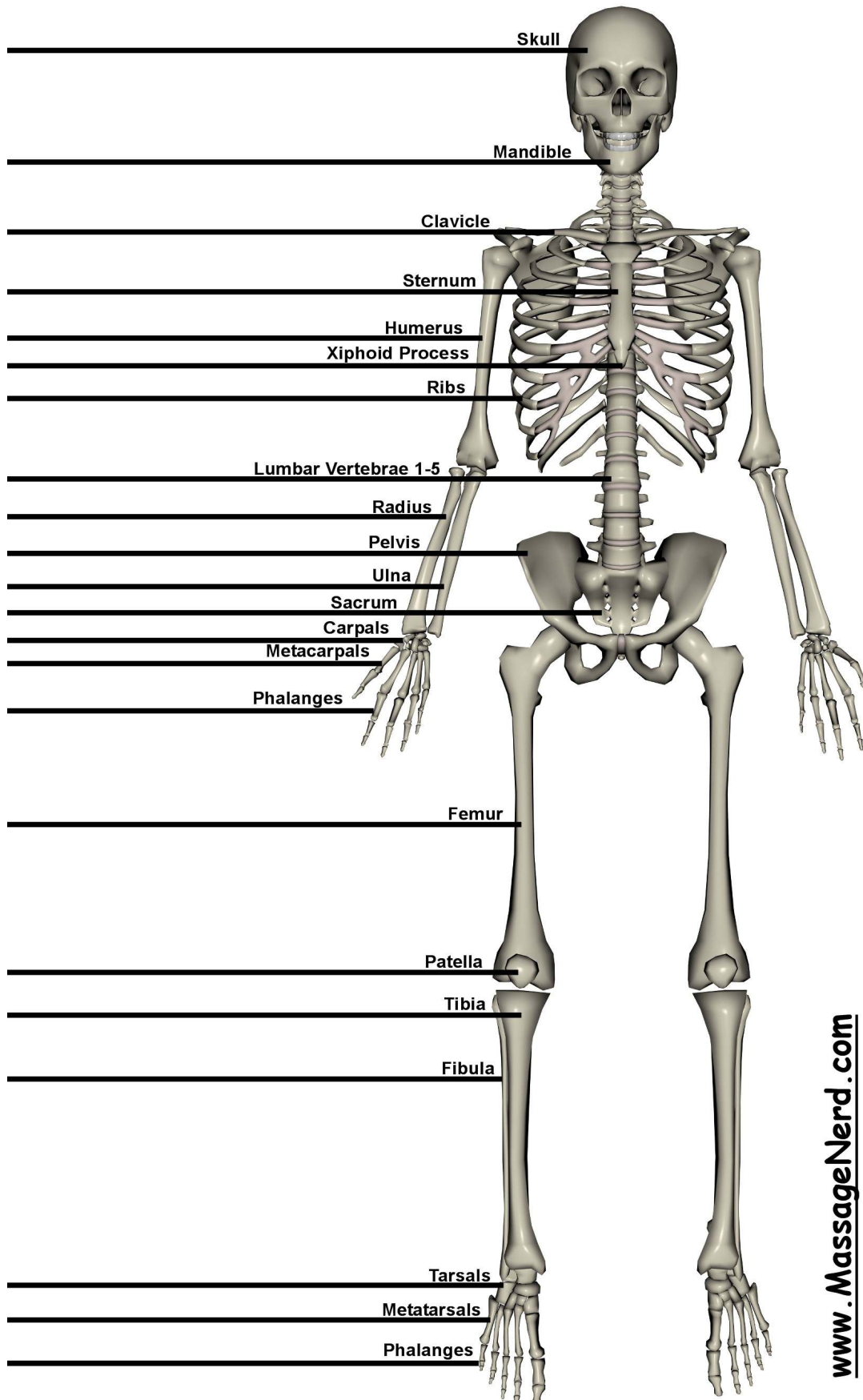
Lateral Malleolus

Medial Malleolus

Calcaneus

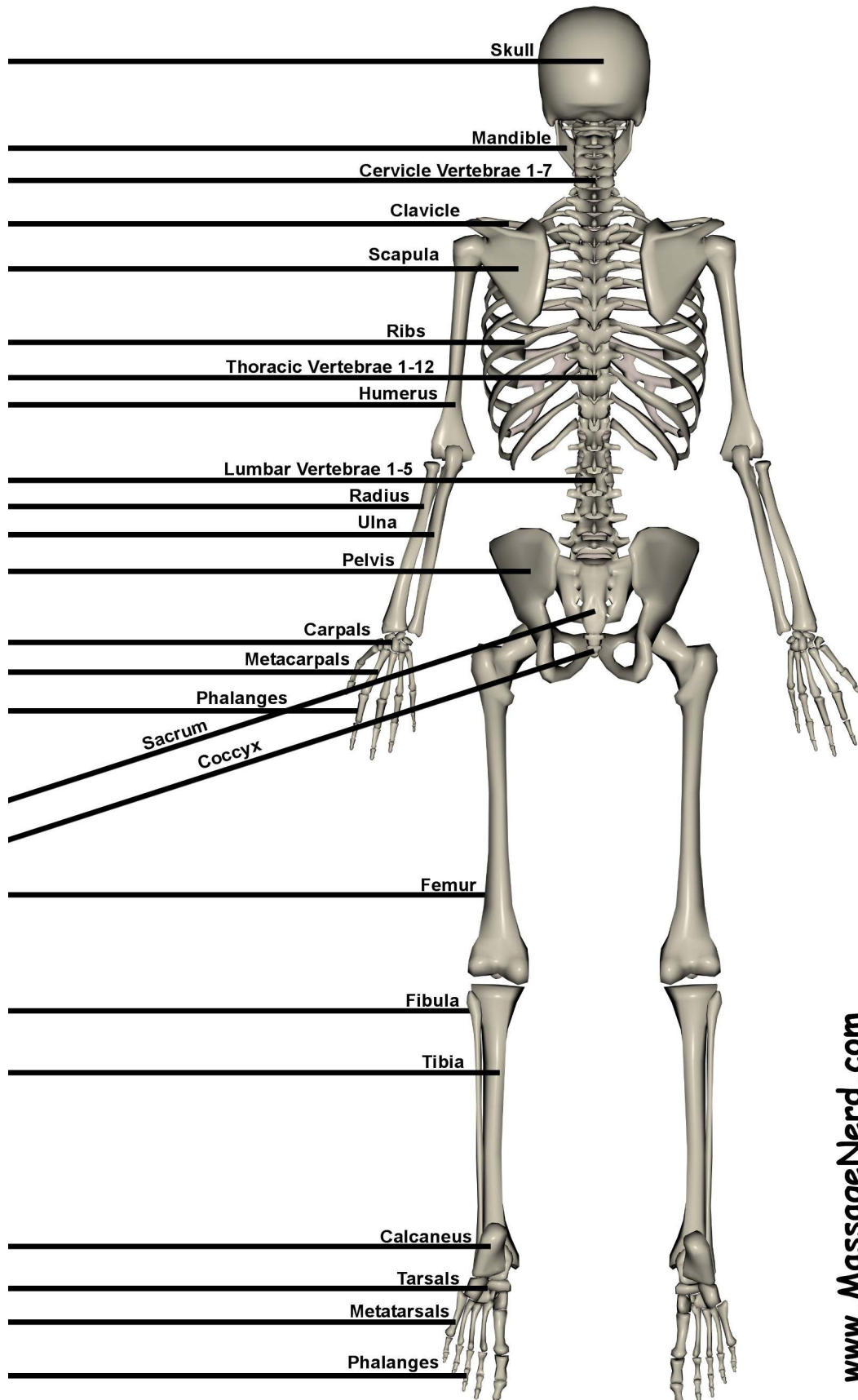
www.MassageNerd.com

Label the Bones

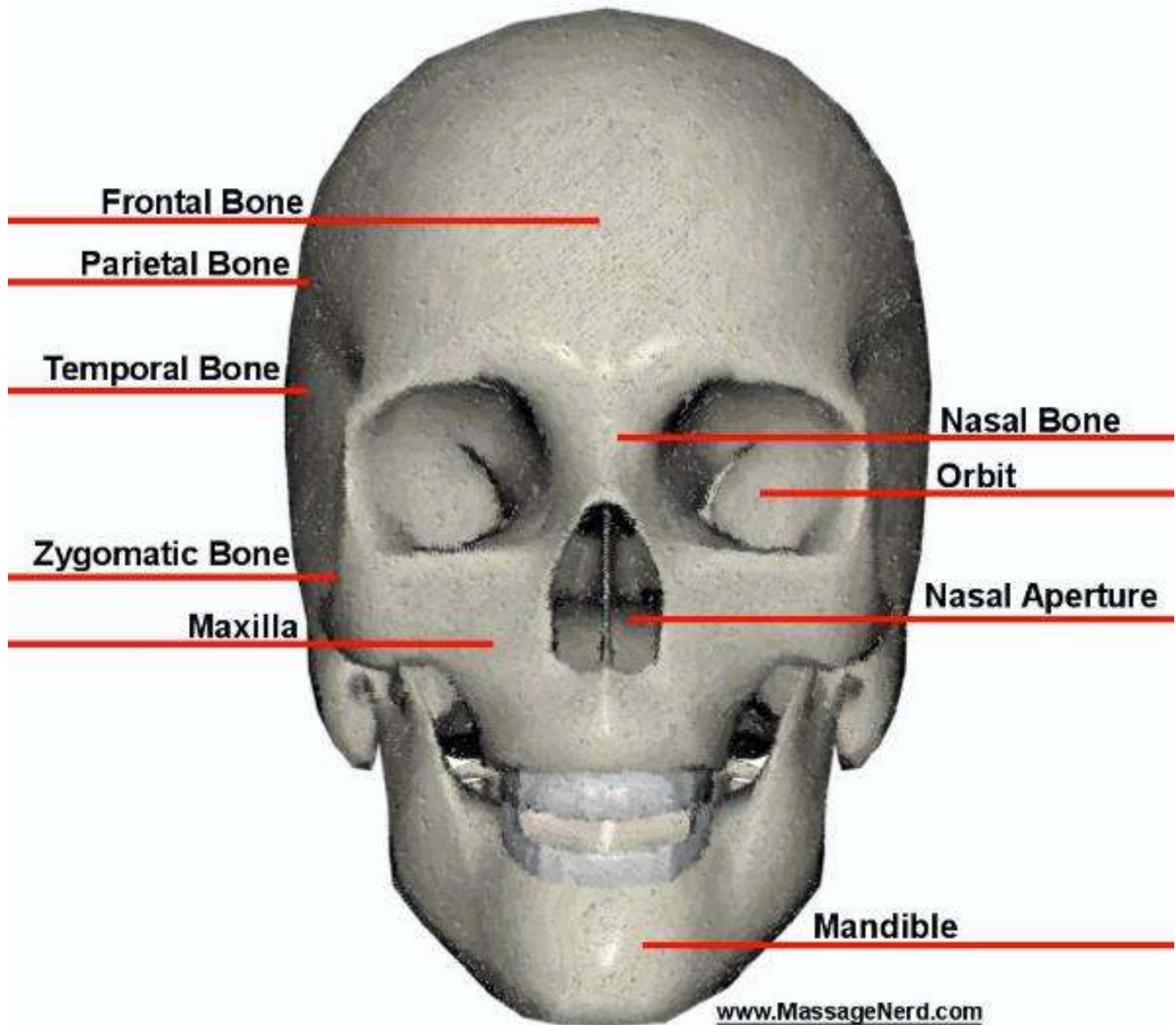


www.MassageNerd.com

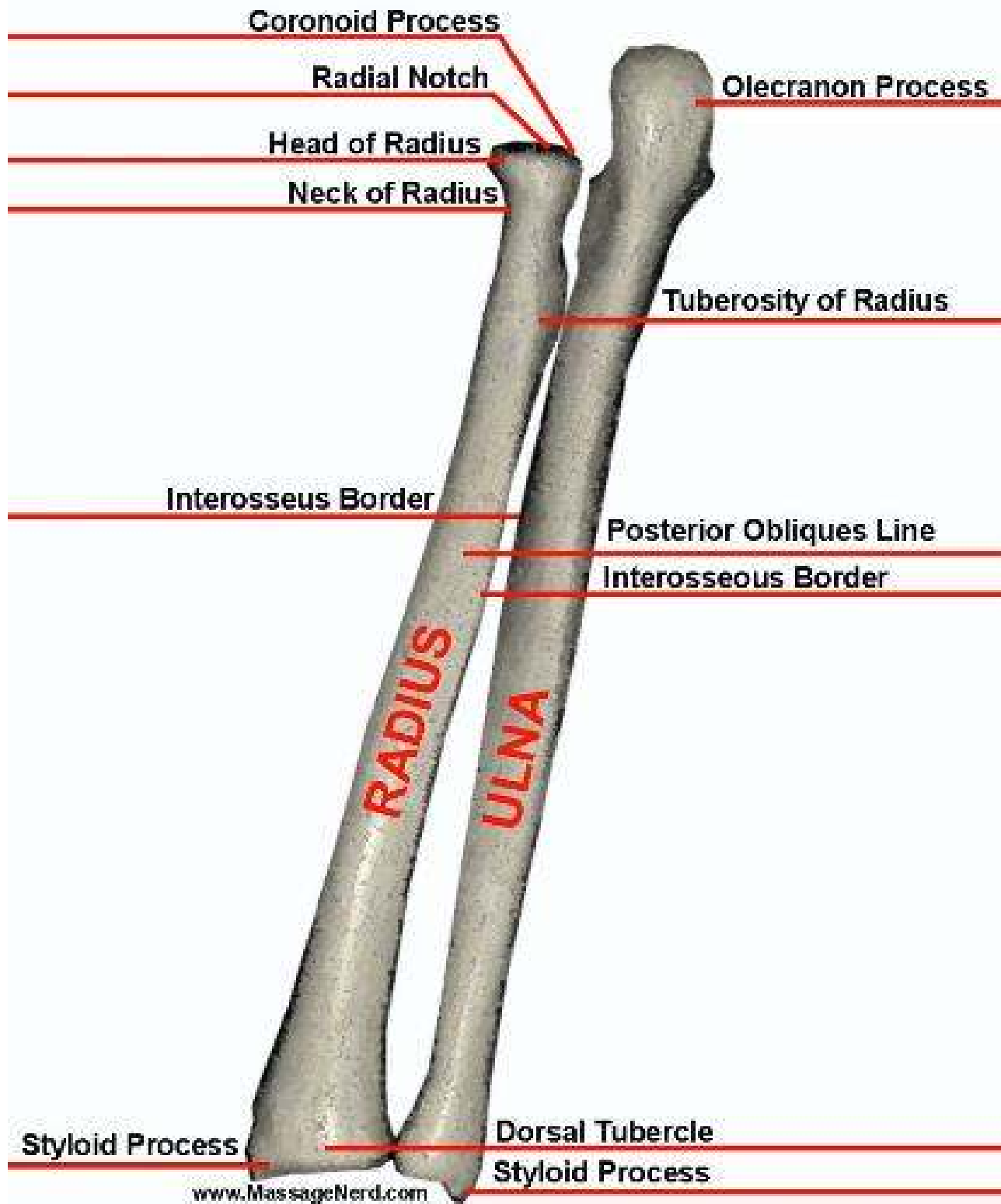
Label the Bones



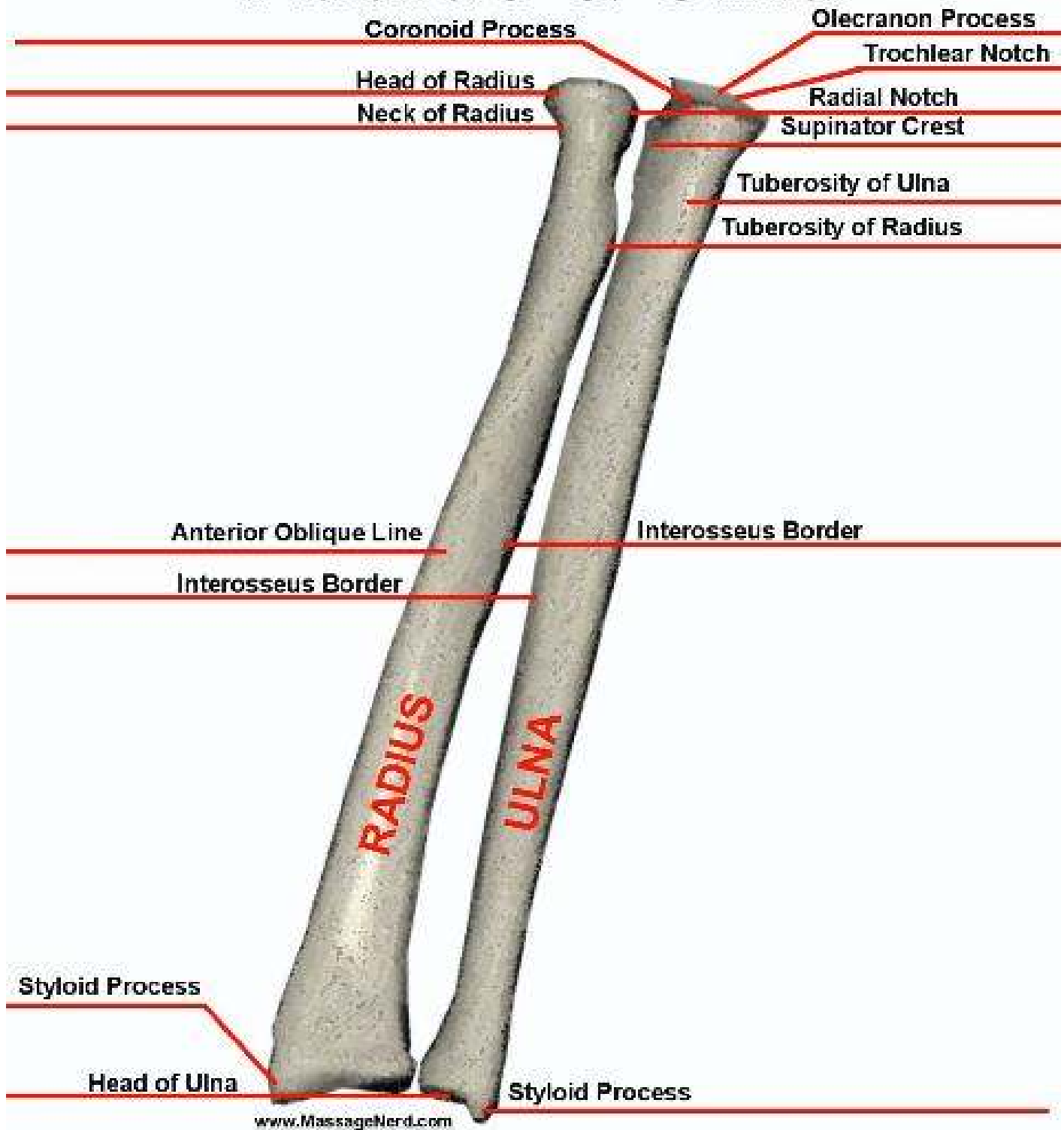
Skull Anterior



Posterior Left Radius & Ulna

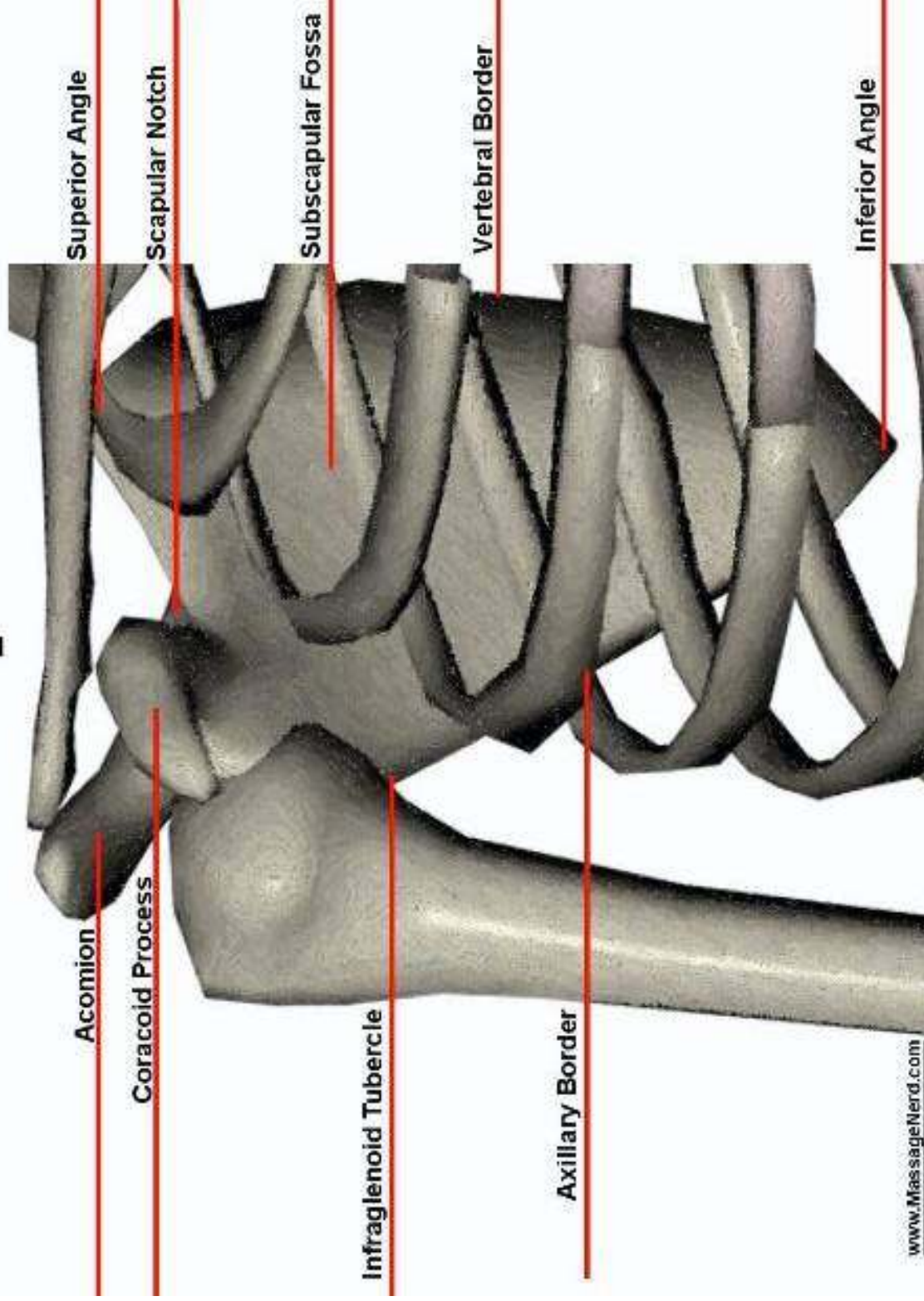


Anterior Right Radius & Ulna

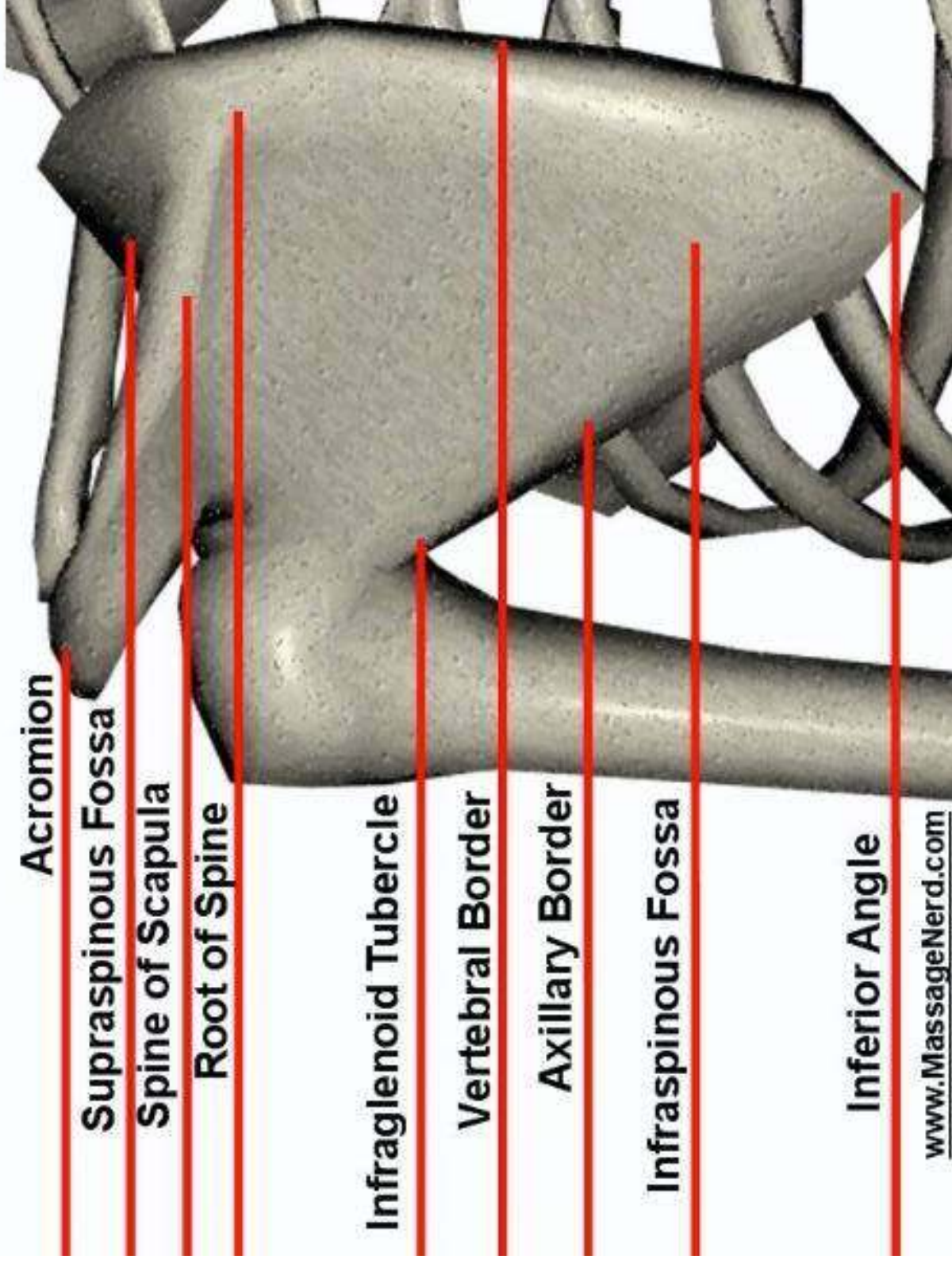


Anterior Right

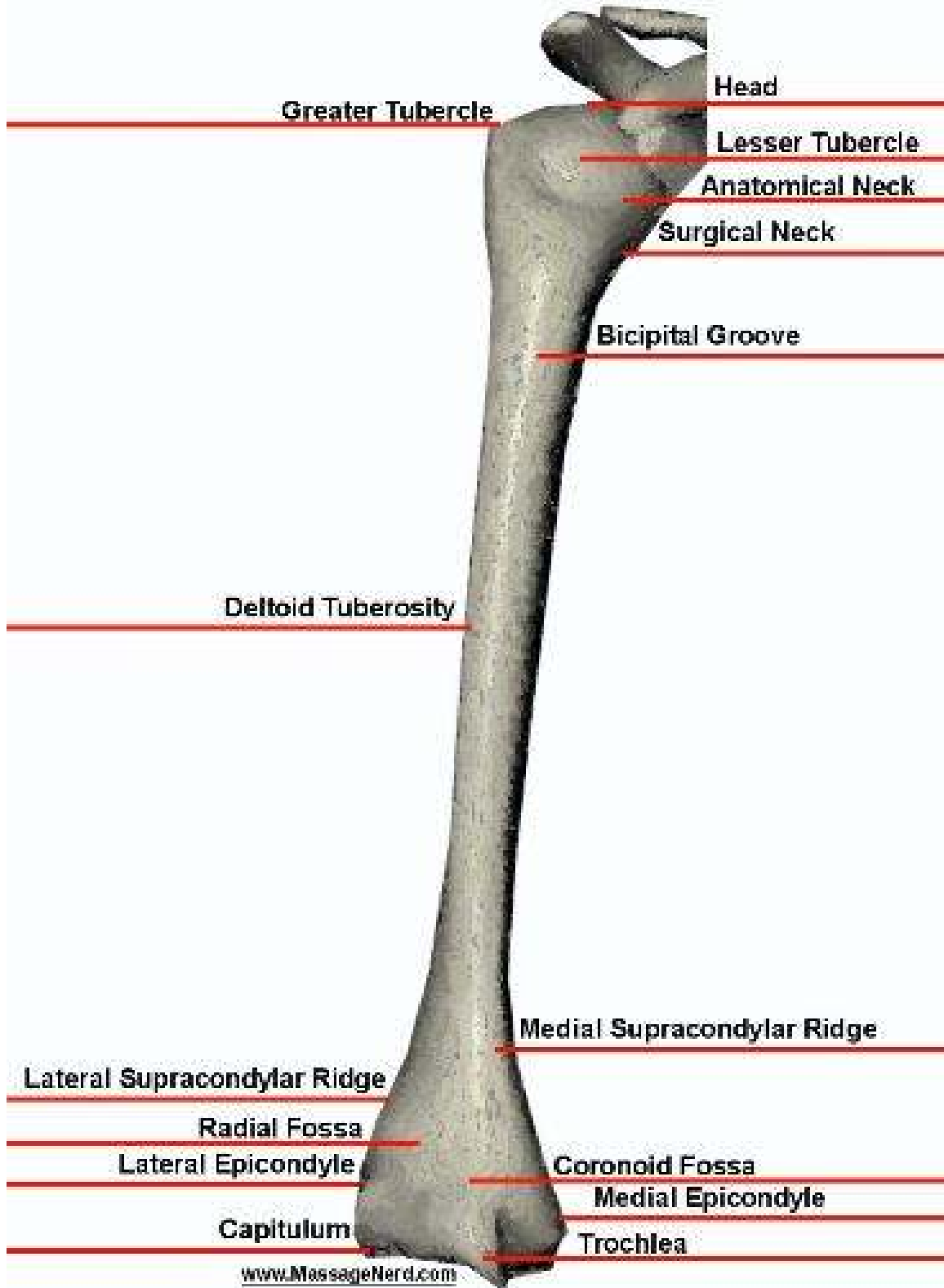
Scapula



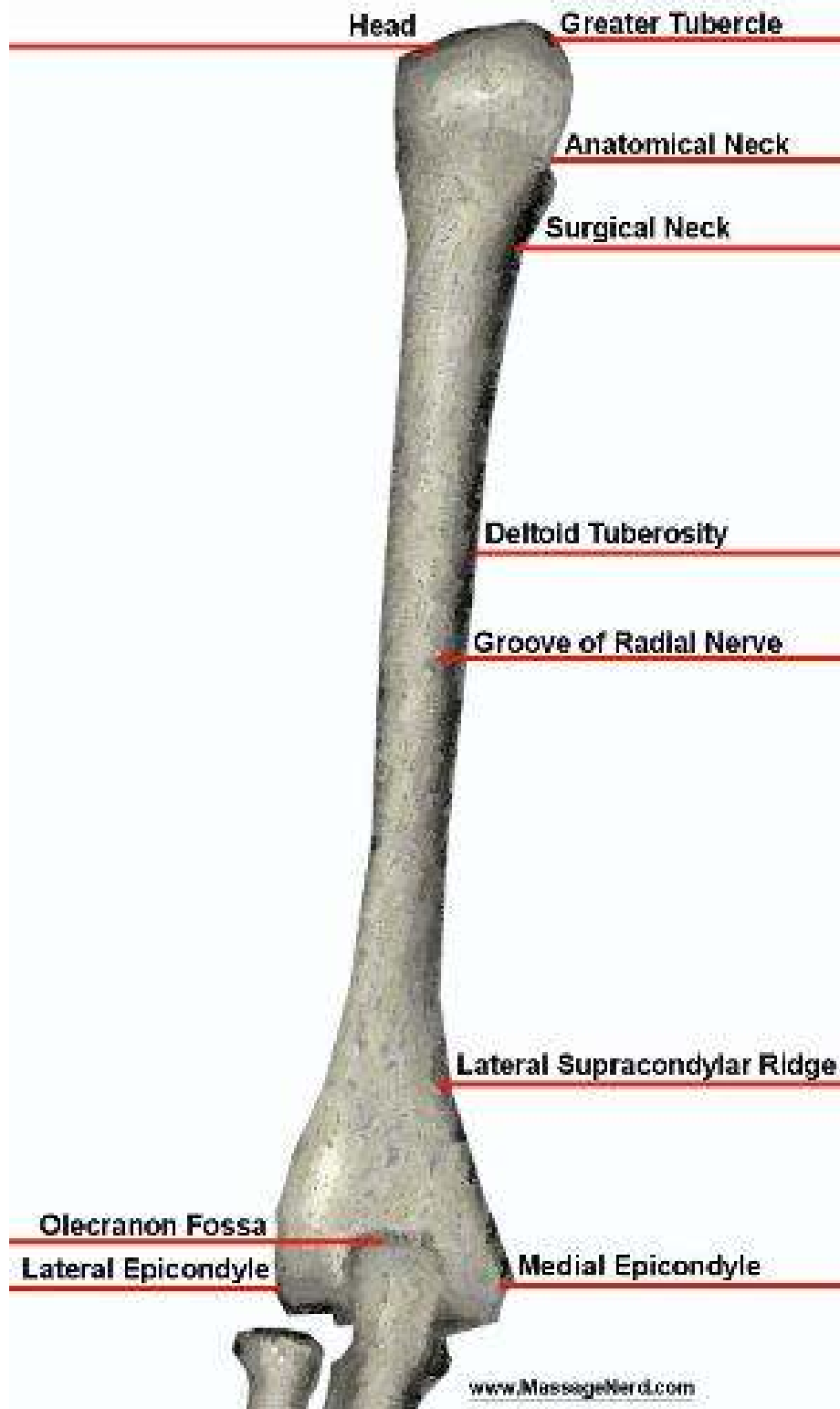
Posterior Left Scapula



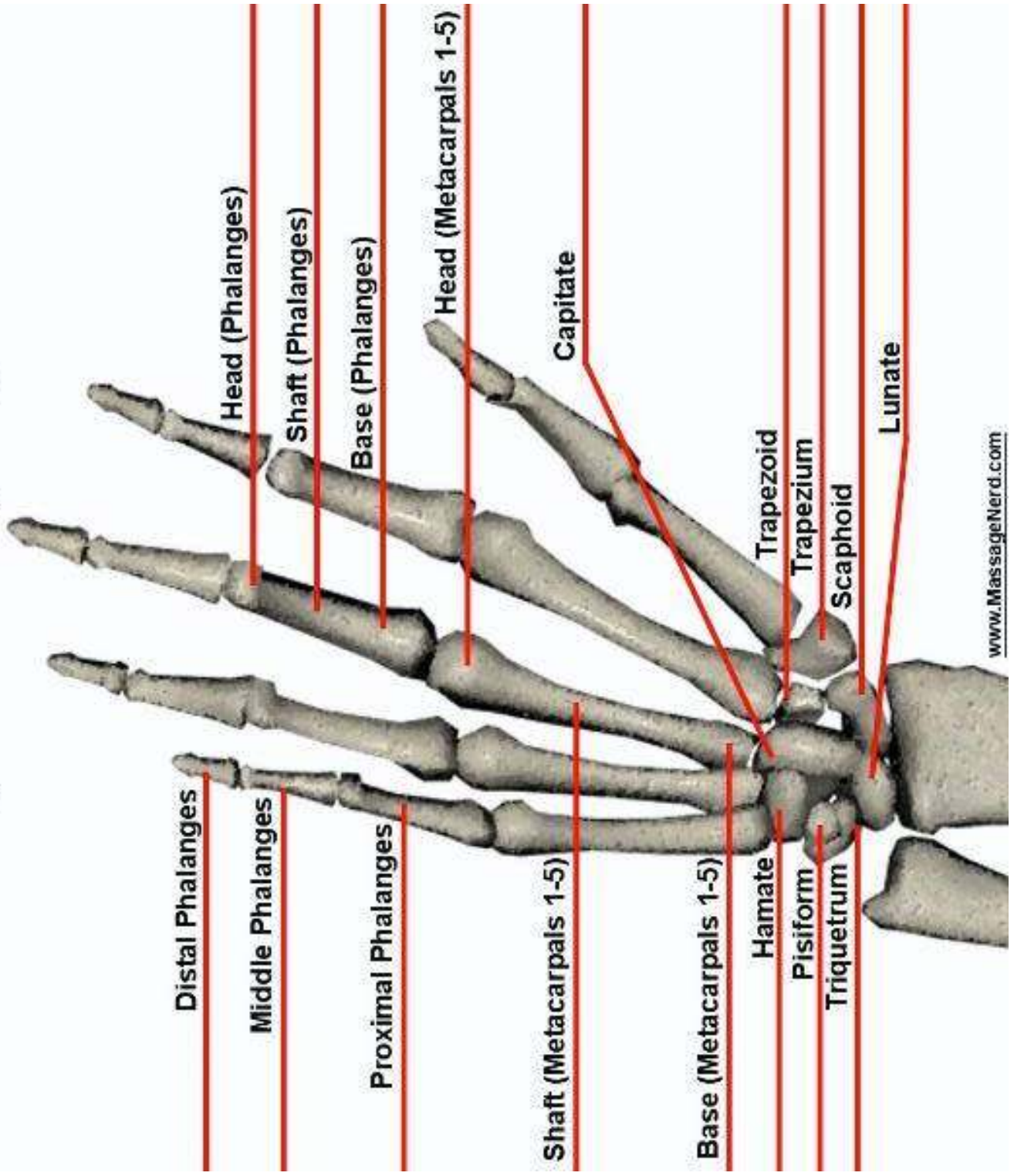
Anterior Right Humerus



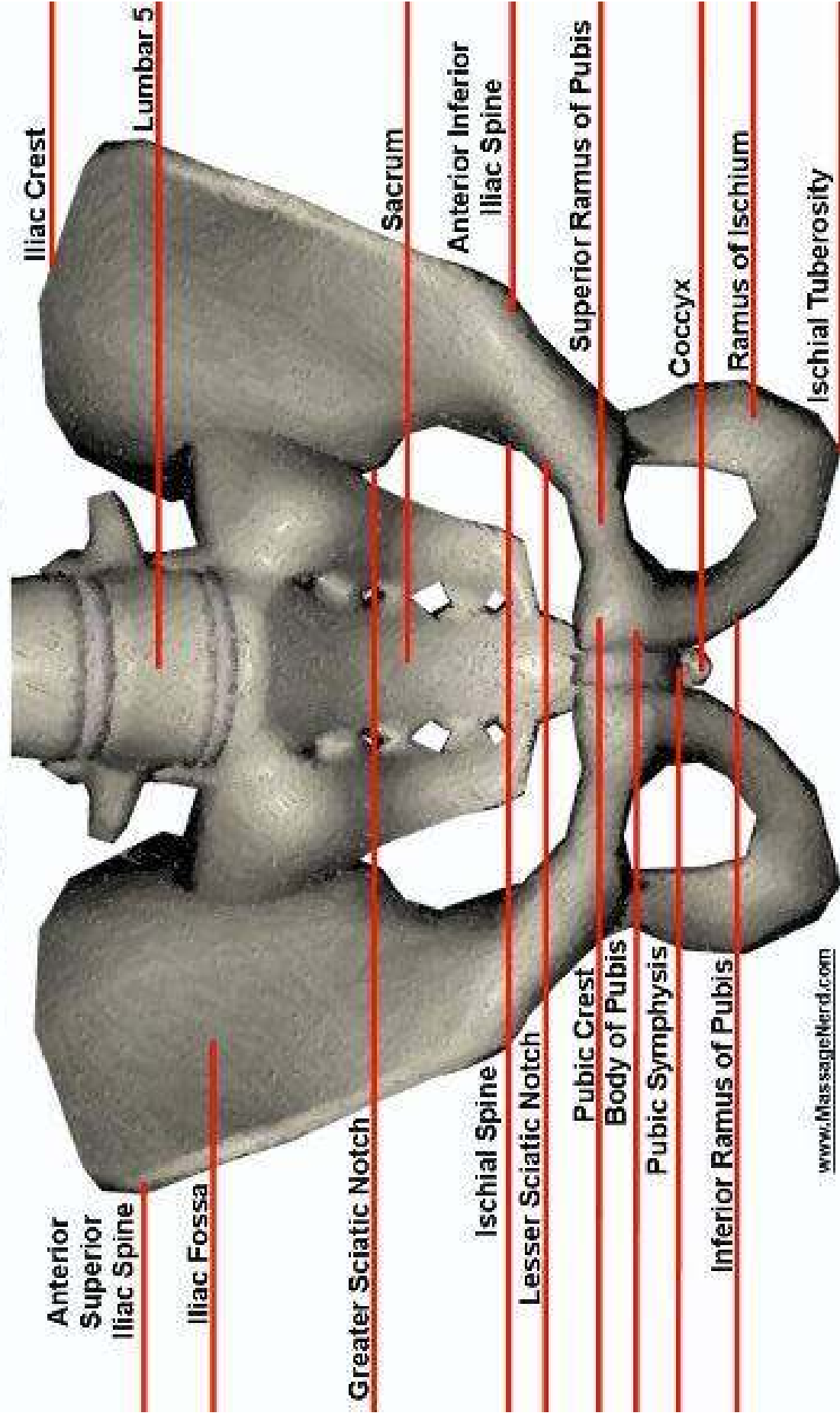
Posterior Left Humerus



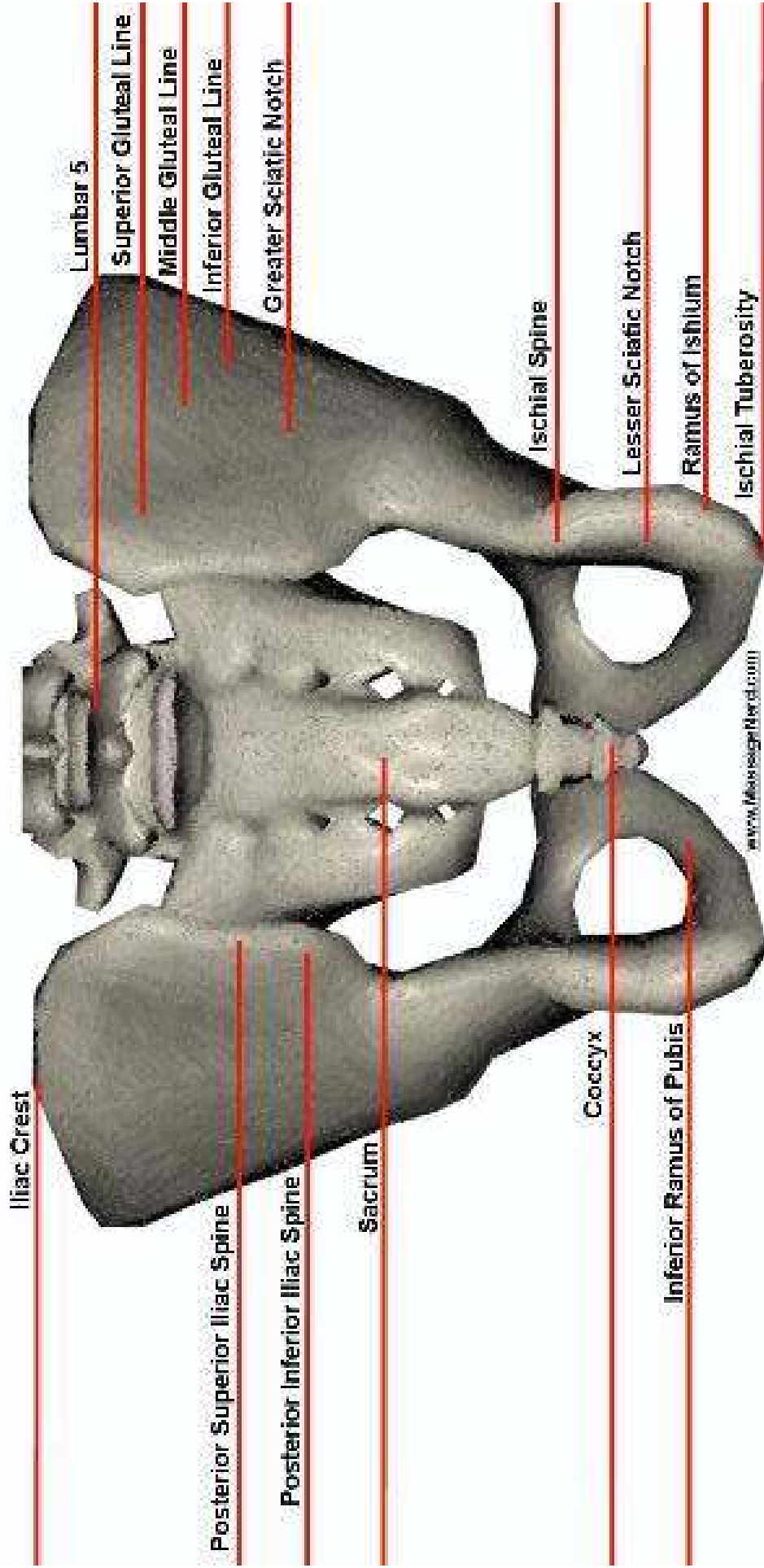
Palmar (Anterior) Right Hand




Anterior Pelvis



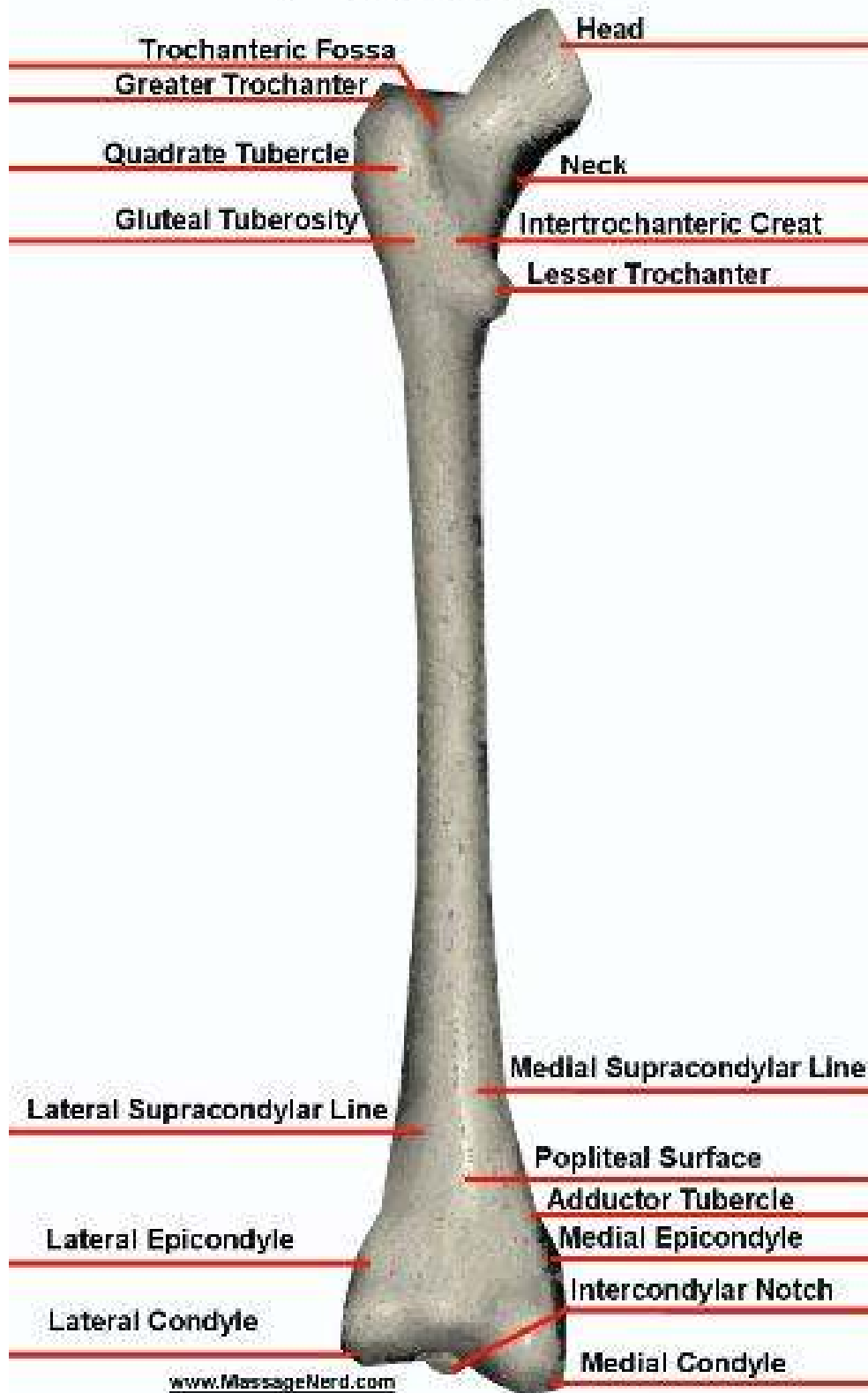
Posterior Pelvis



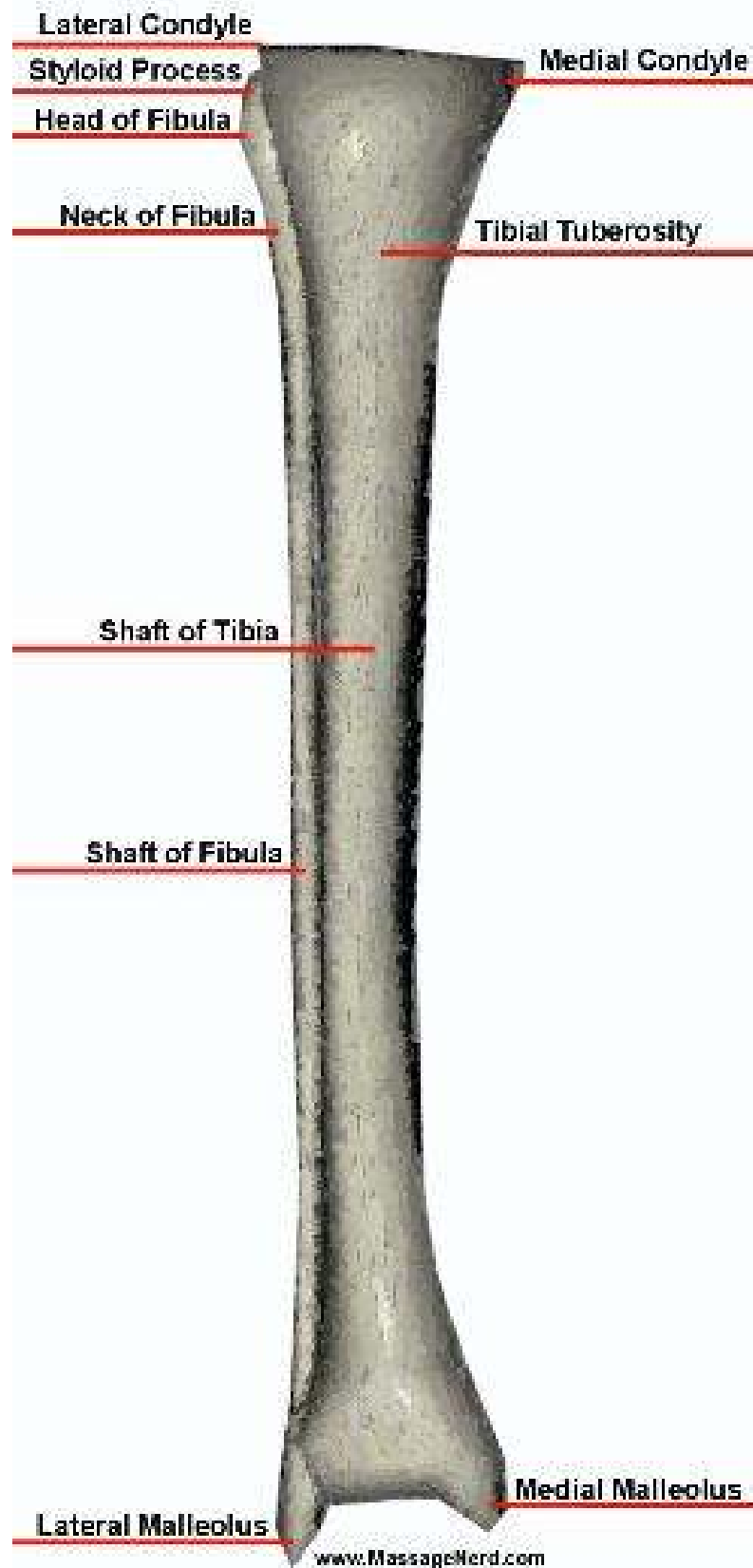
Anterior Right Femur



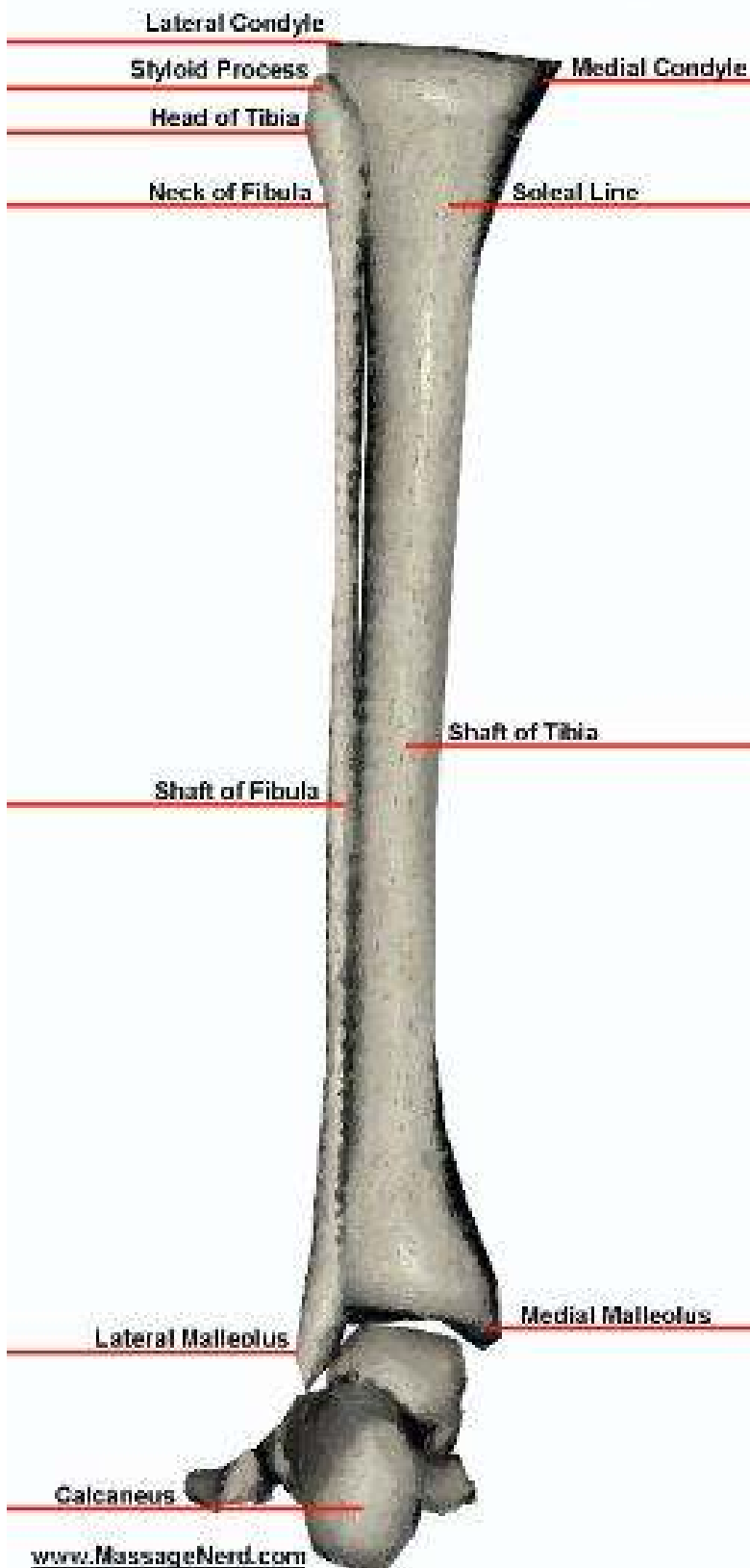
Posterior Left Femur



Anterior Right Tibia & Fibula



Posterior Left Tibia & Fibula



Right Plantar Foot

